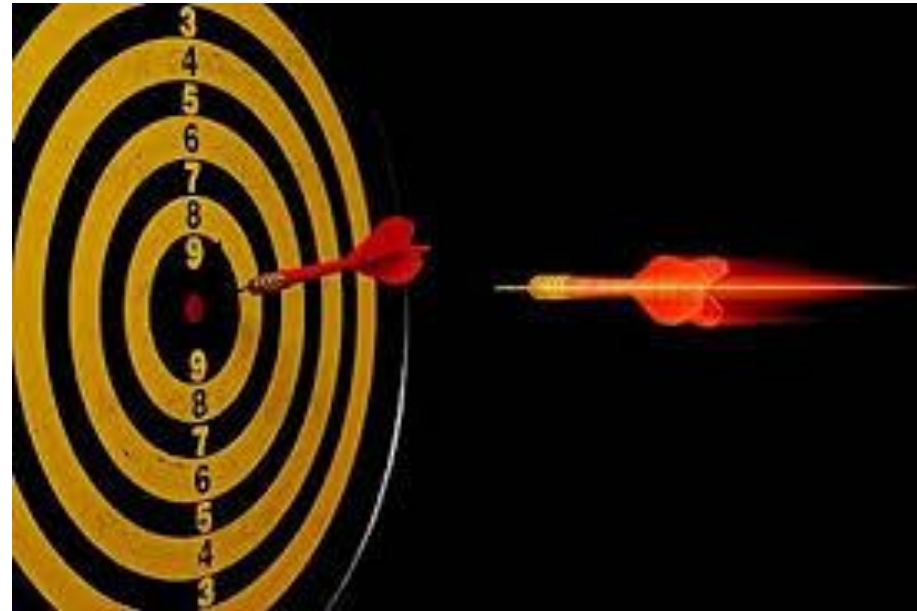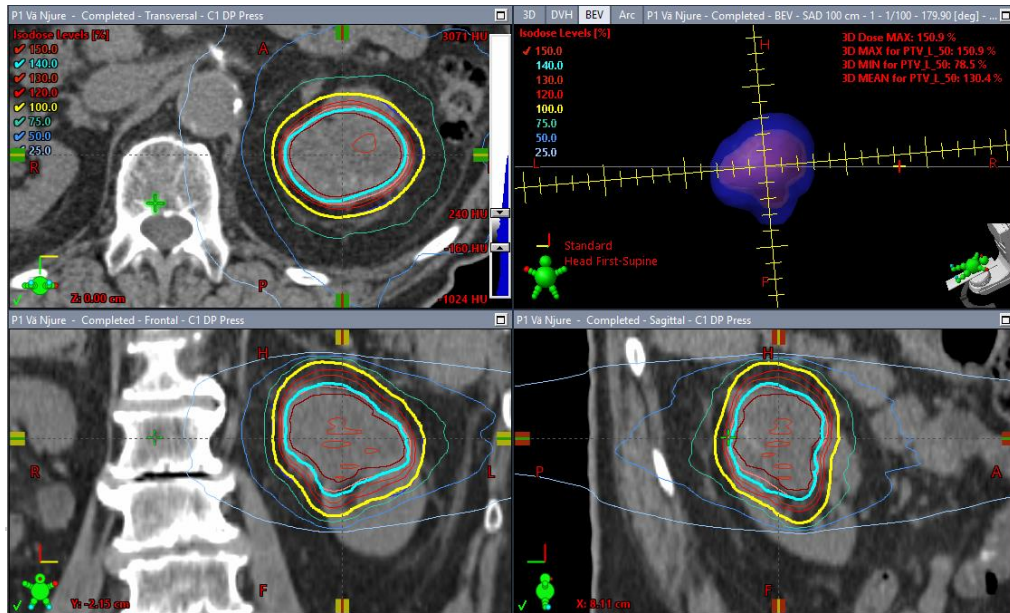


Stereotactic body radiotherapy (SBRT) of renal cell carcinoma



Magnus Lindskog
Head Kidney Cancer Team
Section of genitourinary oncology

Disclosures

- Invited speaker: Ipsen, Pfizer, BMS, MSD
- Advisory Board: BMS, Ipsen, MSD, Pfizer, Eisai
- Research grant: Ipsen

Conclusions – SBRT in Renal cell carcinoma

- Generally safe but careful evaluation of organs at risk
- Patients with comorbidities and/or impaired PS can be treated
- Standard of care for oligometastatic RCC as alternative to metastasectomy
- Option for oligoprogressive RCC
- Useful for primary RCC in medically inoperable patients
- Excellent local control
- Limited effects on GFR
- Alternative to thermal (re-)ablation?

RCC and Radiotherapy – initial results

- Historically considered radioresistant – “RT only for palliation”
- Conventional RT to tumor bed + nodes following nephrectomy
RCC did not improve survival
- Complications were common (stomach, duodenum, liver)
- 19 % mortality rate in RT group (Kjaer, Scand J Urol Nephrol 1987)

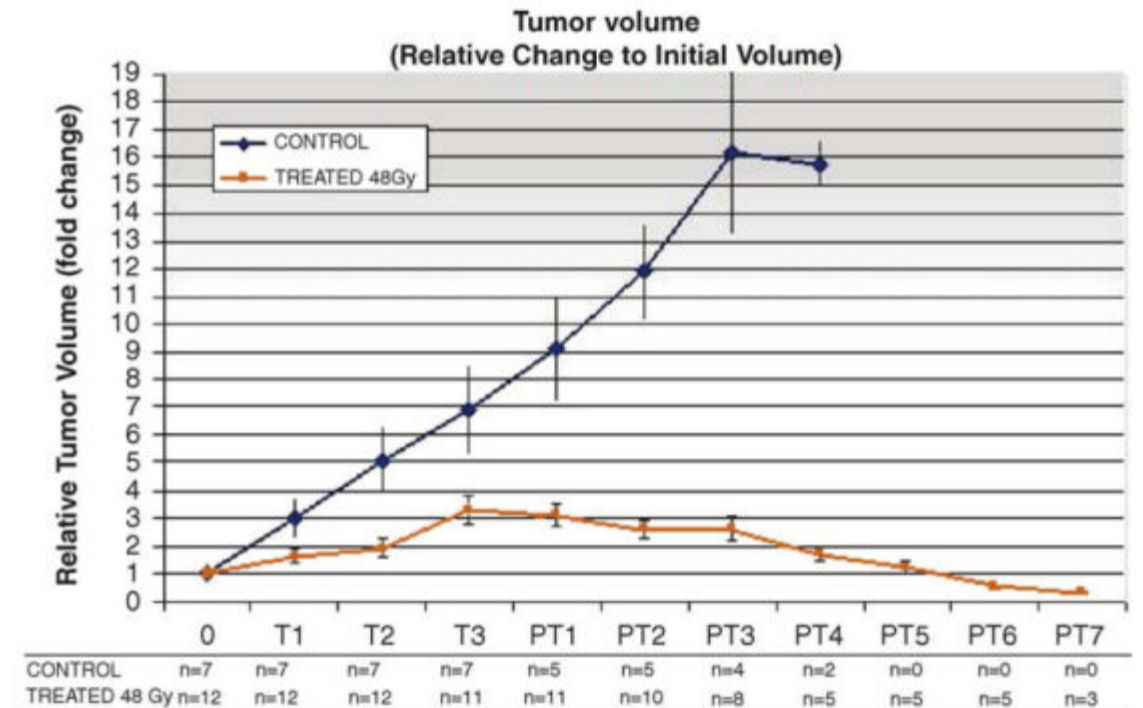
Hypofractionated RT against RCC metastases: Preclinical support



Efficacy of Ablative High-Dose-per-Fraction Radiation for Implanted Human Renal Cell Cancer in a Nude Mouse Model

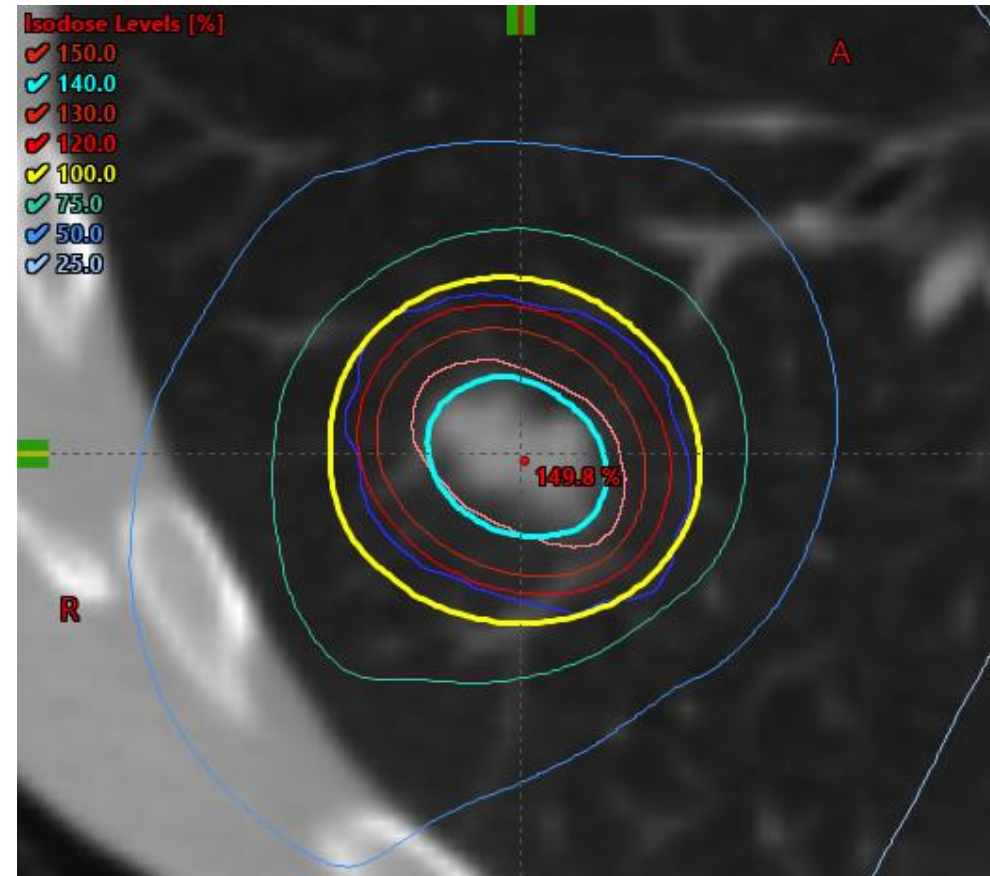
Lance Walsh^a, Jennifer L. Stanfield^a, L. Chinsoo Cho^b, Cheng-hui Chang^b,
Kenneth Forster^b, Wareef Kabbani^c, Jeffrey A. Cadeddu^a, Jer-Tsong Hsieh^a,
Hak Choy^b, Robert Timmerman^b, Yair Lotan^{a,*}

- nude mice
- human RCC xenografts
- 16 Gy x 3 vs observation



SBRT

- What characterises SBRT compared to conventional RT?
- High precision
- High biological dose
- Dose escalation within the tumor
- Few fractions



ORIGINAL ARTICLE



A prospective Phase II trial of using extracranial stereotactic radiotherapy in primary and metastatic renal cell carcinoma

CHRISTER SVEDMAN¹, PER SANDSTRÖM¹, PAVEL PISA^{1,2}, HENRIC BLOMGREN³,
INGEMAR LAX⁴, KARL-MIKAEL KÄLKNER¹, STEN NILSSON^{1,2} & PETER WERSÄLL^{1,4}

¹Department of General Oncology, Radiumhemmet, Karolinska University Hospital, Stockholm, Sweden, ²Cancer Center Karolinska, Karolinska Institute, Stockholm, Sweden, ³Malzoni Radiosurgery Institute, Agropoli, Italy and ⁴Department of Radiotherapy, Radiumhemmet, Karolinska University Hospital, Stockholm, Sweden

EXTRACRANIAL STEREOTACTIC RT | VOLUME 77, ISSUE 1, P88-95, OCTOBER 01, 2005

Extracranial stereotactic radiotherapy for primary and metastatic renal cell carcinoma

Peter J. Wersäll   • Henric Blomgren  • Ingmar Lax  • ... Ingemar Näslund • Pavel Pisa •

Christer Svedman • [Show all authors](#)

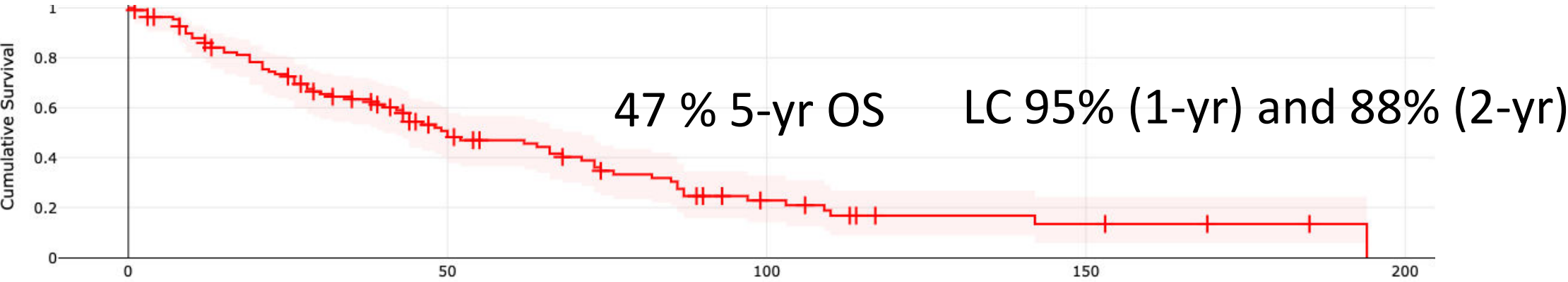
Published: June 21, 2005 • DOI: <https://doi.org/10.1016/j.radonc.2005.03.022>

Conclusions

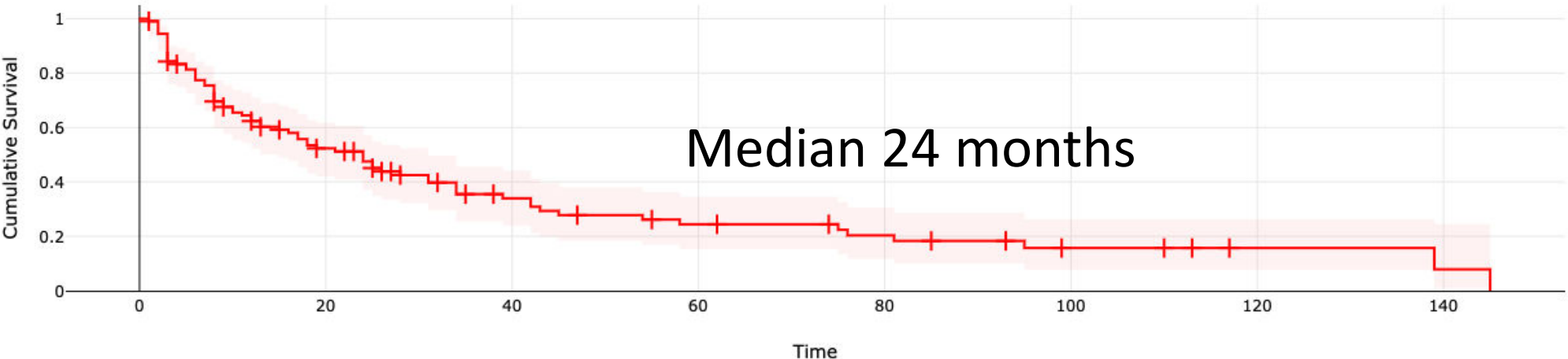
Our use of SRT for patients with primary and metastatic RCC yielded a high local control rate with low toxicity. Patients with one to three metastases, local recurrences after nephrectomy or inoperable primary tumors benefited the most, i.e. had fewer distant recurrences (13/23) and longer survival times compared to patients with >3 metastases (24/27 recurrences).

Effects of stereotactic radiotherapy (SRT) as first intervention against oligometastatic renal cell carcinoma

(data from Karolinska)



Time from SRT to start of next line of treatment



› [Lancet Oncol.](#) 2024 May;25(5):e193-e204. doi: 10.1016/S1470-2045(24)00023-8.

Delphi consensus on stereotactic ablative radiotherapy for oligometastatic and oligoprogressive renal cell carcinoma—a European Society for Radiotherapy and Oncology study endorsed by the European Association of Urology

Renal Cancer is Not Radioresistant: Slowly but Continuing Shrinkage of the Tumor After Stereotactic Body Radiation Therapy

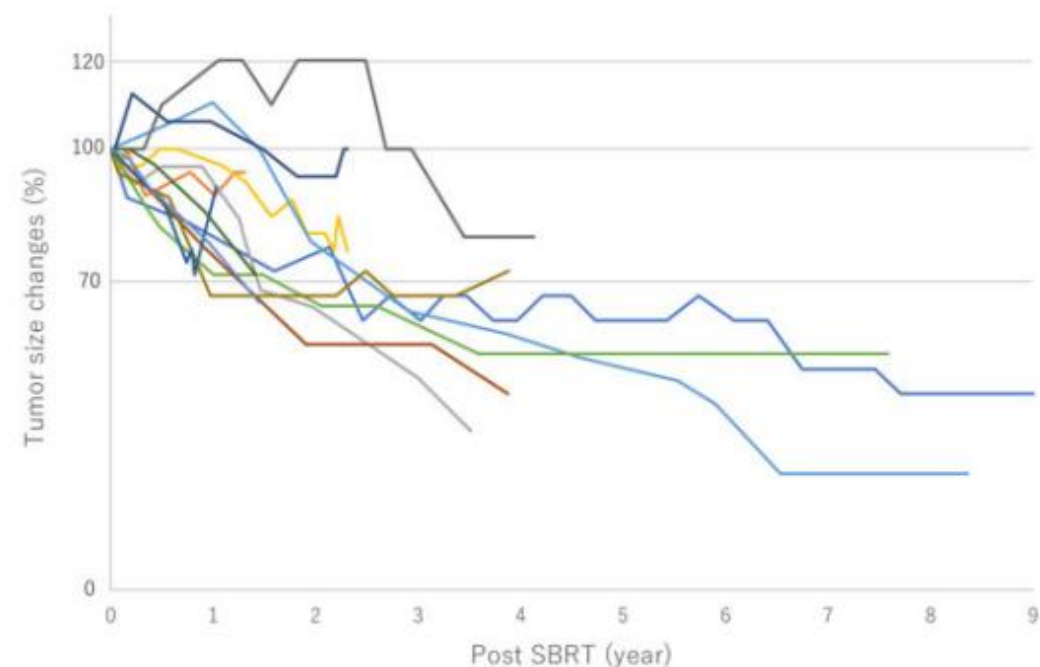
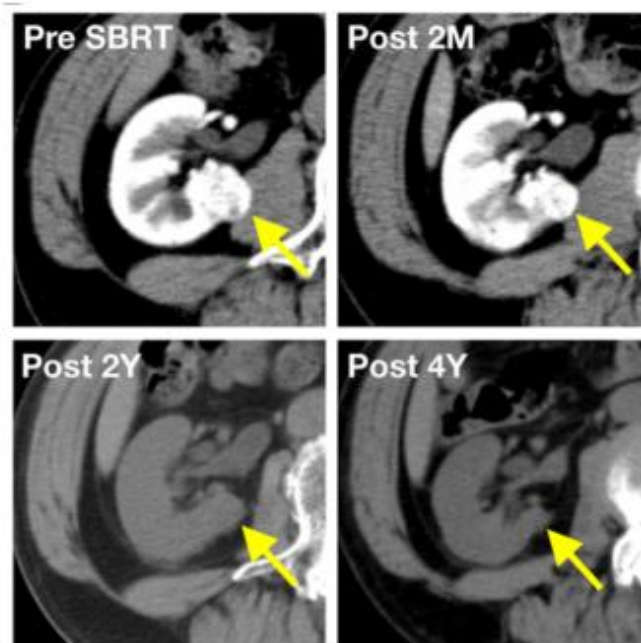
Satoshi Funayama, MD¹, Hiroshi Onishi, MD, PhD¹, Kengo Kuriyama, MD, PhD², Takafumi Komiyama, MD, PhD³, Kan Marino, MD¹, Masayuki Araya, MD, PhD³, Ryo Sai Shinichi Aoki, MD¹, Yoshiyasu Maehata, MD, PhD¹, Hotaka Nonaka, MD, PhD⁴, Licht Tominaga, MD, PhD⁵, Juria Muramatsu, MD¹, Hiroshi Nakagomi, MD, PhD⁶, Manabu Kamiyama, MD, PhD⁶, and Masayuki Takeda,

Technology in Cancer Research & Treatment

Volume 18: 1-8

© The Author(s) 2019

- Primary stage I RCC (n=13)
- 6-7 Gy x 10
- Slow but continuous shrinkage



Stereotactic body radiotherapy for primary renal cell carcinoma: a systematic review and practice guideline from the International Society of Stereotactic Radiosurgery (ISRS)

Shankar Siva¹, Alexander V Louie², Rupesh Kotecha³, Melissa N Barber⁴, Muhammad Ali⁵, Zhenwei Zhang⁶, Matthias Guckenberger⁷, Mi-Sook Kim⁸, Marta Scorsetti⁹, Alison C Tree¹⁰, Ben J Slotman¹¹, Arjun Sahgal², Simon S Lo¹²

- 36 publications included
 - 23 retrospective
 - 13 prospective
- N=822 patients

	Inclusion criteria	Exclusion criteria
Patient or study population, or problem	Adults >18 years; renal cell carcinoma stage I-IV disease	Paediatric patients; non-renal cell carcinoma histology
Intervention	SABR targeting primary renal tumour; dose per fraction (≥ 5 Gy)	SABR targeting metastatic sites
Comparison or control	NA	NA; no comparative-effectiveness or randomised studies published
Outcomes	Local control; progression-free survival; overall survival; assess treatment-related toxicity, renal function, and radiotherapy treatment details	NA
Study design	Reports at least one of the above-listed outcomes; prospective clinical trials; cohort studies (retrospective and prospective); case series (\geq two patients); published abstracts	Reviews, meta-analyses, and guidelines; case reports (<two patients); dosimetric, motion-management, or radiotherapy planning studies; basic science or preclinical studies

SABR=stereotactic ablative body radiotherapy. NA=not applicable.

Table 1: Population, intervention, comparison, outcomes, and study design criteria for study selection

Systematic review (Siva et al, 2024)

- N=822
- Median age 72 yr (62-83)
- 73% male
- Median tumor diam 4.4 cm
- Median Follow-up 31 months

Systematic review (Siva et al, 2024), n=822

SBRT of primary RCC - Treatment efficacy

- Local control: 94% (interval 70,0-100)
- PFS at 5 yr: 81% (95% CI 0,72-0,92) – 6 studier
- OS at 5 yr 77% (95% CI 0,65-0,89) – 12 studier

Systematic review (Siva et al, 2024), n=822

Toxicity of SBRT to primary RCC

- Grade 2 in 5,3%
- Grade 3 in 2,7%
- Grade 4 in 0,7%
- 3,9% in dialysis

Stereotactic ablative body radiotherapy for inoperable primary kidney cancer: a prospective clinical trial

Shankar Siva^{*,†}, Daniel Pham^{*}, Tomas Kron^{*,†}, Mathias Bressel^{*}, Jacqueline Lam^{*}, Teng Han Tan^{*}, Brent Chesson^{*}, Mark Shaw^{*}, Sarat Chander^{*}, Suki Gill^{*,‡}, Nicholas R. Brook[§], Nathan Lawrentschuk^{*,¶}, Declan G. Murphy^{*,†} and Farshad Foroudi^{*,¶}

^{*}Peter MacCallum Cancer Centre, Melbourne, Vic., Australia, [†]Sir Peter MacCallum Department of Oncology, University of Melbourne, Melbourne, Vic. Australia, [‡]Sir Charles Gairdner Hospital, Nedlands Perth, WA, Australia, [§]Royal Adelaide Hospital, Adelaide, SA, Australia, and [¶]Olivia Newton John Cancer Centre, Heidelberg, Vic., Australia

Table 2 Treatment-related adverse events according to period (acute and late) and overall.

Adverse event	Acute (≤ 90 days after SABR)			Late (> 90 days after SABR)			Overall		
	Grade 1	Grade 2	Grade 3	Grade 1	Grade 2	Grade 3	Grade 1	Grade 2	Grade 3
Abdominal pain	0	0	0	0	1	0	0	1	0
Back pain	0	0	0	0	0	0	0	0	0
<u>Chest wall pain</u>	5	0	0	12	0	0	15	0	0
Dermatitis	2	0	0	0	0	0	2	0	0
Diarrhoea	3	0	0	1	0	0	3	0	0
Dizziness	0	0	0	0	0	0	0	0	0
Dizzy	0	0	0	0	0	0	0	0	0
Dyspnoea	0	1	0	2	0	0	2	1	0
<u>Fatigue</u>	11	6	0	7	0	1	14	5	1
Gastritis	1	1	0	1	0	0	2	1	0
Haematuria	0	0	0	3	1	0	3	1	0
Left flank pain	0	0	0	0	0	0	0	0	0
<u>Nausea</u>	5	2	0	2	0	0	5	2	0
Pneumonia	0	0	0	0	0	0	0	0	0
Right flank pain	1	0	0	0	0	0	1	0	0
Skin induration	0	0	0	1	0	0	1	0	0
At least one event, n (%)	11 (33)	7 (21)	0	17 (52)	2 (6)	1 (3)	19 (58)	7 (21)	1 (3)

SABR, stereotactic ablative body radiotherapy.

Patients with a solitary kidney – data från Correa et al 2018

- Retrospective cohort, n=81 with solitary kidney
- Baseline GFR 65 ml/min
- After SBRT, mean estimated [glomerular filtration](#) rate decrease was -5.8 mL/min (-9% from baseline)
- None of the patients required dialysis

- A dose–response relationship exists between the irradiated kidney cortical parenchyma volume and functional decline
- Imaging indicates renal cortical function is spared to regions with absorbed radiation dose values below 50% of the prescription dose (13 Gy of a single 26 Gy fraction)

Recommendations

- Tumor \leq 4-5 cm: Suggested optimal dose 26 Gy in single fraction*
- Larger tumors: 48 Gy in three fractions (40 Gy in five fractions if constraints not met for OAR)
- For patients with solitary kidney: approaches to reduce the volume of irradiated kidney
- A routine post-SBRT biopsy should not be performed
- Optimal follow-up: CT every 6 months

SBRT as treatment of local recurrence after thermal ablation?

Multicenter Study [BJU Int. 2025 Jan; 135\(1\):110-116. doi: 10.1111/bju.16520. Epub 2024 Aug 26.](#)

Salvage stereotactic ablative body radiotherapy after thermal ablation of primary kidney cancer

Muhammad Ali^{1 2}, Young Suk Kwon³, Kendrick Koo¹, Anna Bruynzeel^{4 5}, David Pryor⁶, Daniel G Schep⁷, Michael Huo⁶, Maggie Stein³, Anand Swaminath⁷, Raquibul Hannan³, Shankar Siva^{1 2}

Affiliations + expand
PMID: 39187428 DOI: [10.1111/bju.16520](#)

Abstract

Objective: To evaluate the effectiveness and safety of salvage stereotactic ablative body radiotherapy (SABR) for recurrent renal cell carcinoma (RCC) after thermal ablation (TA).

Materials and methods: This study was a multi-institutional retrospective analysis of patients with recurrent RCC following TA who received SABR between 2016 and 2020. The primary study outcome was freedom from local failure, evaluated radiographically based on Response Evaluation Criteria in Solid Tumours (RECIST) v1.1. Distant failure, cancer-specific survival (CSS), overall survival (OS), treatment-related toxicity and renal function changes following SABR were the secondary outcomes. The Kaplan-Meier method was used to estimate freedom from local and distant failure, CSS and OS.


N=18

At 3yrs FU:

100% LC

72% distant progression-free survival

92% CSS

med GFR_{pre} 58  GFR_{post} 48 mL/min (-17%)

No grade 3+ toxicity



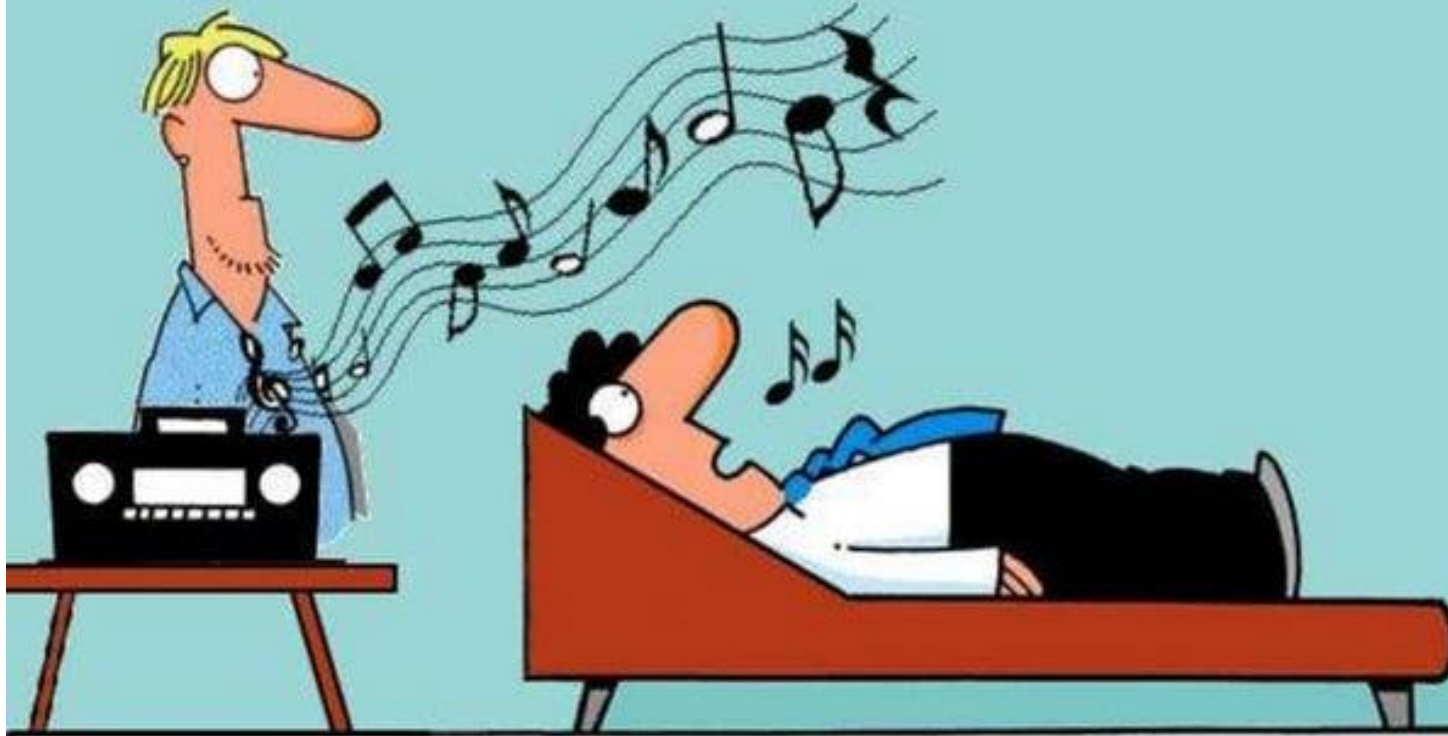Advantages of SBRT in RCC

- + Safe and minimally toxic
- + very high local control rates
- + no definitive size limitation
- + not limited by location
- + alternative for unresectable tumors
- + suitable for medically inoperable pts
- + feasible if solitary kidney

Limitations of SRT in RCC

- Stringent technical requirements
- Stringent quality assurance
- intensive training of whole RT team
- No histological confirmation
- No randomized data

Radiotherapy



George sang along to the tune, wondering what the big deal was about Radiotherapy

magnus.lindskog@regionstockholm.se